

## **Potential Sources for Vein Transposition in Microsurgery**

AYMAN A. SHAKER, M.D.

*The Department of Plastic and Reconstructive Surgery, Faculty of Medicine, Ain Shams University.*

### **ABSTRACT**

This study discusses the problem of venous anastomosis in microsurgery. There are certain circumstances where there is no available suitable vein for the venous anastomosis. In these cases interpositional vein graft can be used but it carries a higher risk of thrombosis. Vein transposition from the nearby areas can offer another alternative that has many advantages over interpositional vein grafting. These advantages include; only one venous anastomosis is required, a long pedicle can be harvested, the vein is located outside the ablative surgical field or radiated tissue, the vein caliber is well suited for microvascular anastomosis and the drainage will be to a high-flow, low pressure system. Vein transposition is indicated even in the presence of local veins when they are damaged, insufficient in number, their use can jeopardize venous drainage or after failure of anastomosing them. The most commonly used veins are the cephalic vein in head and neck and breast reconstruction, the external jugular vein in head and neck reconstruction, the superficial inferior epigastric vein and the saphenous vein in penile replantation and reconstruction and the dorsal digital veins in digital replantation and reconstruction. In this paper the author will discuss his experience in this technique and evaluate the advantages of the technique.

### **INTRODUCTION**

For experienced surgeon, free composite tissue transfers offer a reliable, single-stage reconstruction with low morbidity. Adequate recipient arteries and veins are essential in obtaining a successful flap transfer. However, under certain circumstances there is no available suitable recipient vein for the venous anastomosis. This is commonly met in reconstructive surgery of the head and neck following cancer ablation. Though the neck offers several venous recipients outflowing through the internal jugular system, for example, the common facial, retro-mandibular and superior thyroid veins, sometimes there is no adequate local veins. This may be due to indurated scarred neck from prior surgery, radical neck dissection, cervical soft tissue

infection, radiation therapy or a combination of these [1]. This problem was overcome by transposition of the cephalic vein as sole venous drainage of the free flap. This technique has been published as isolated case reports in the literature [2-4] and thoroughly described by Kim and Chandrasekhar [1].

In this study we are going to describe other circumstances in which vein transposition are indicated.

### **PATIENTS AND METHODS**

#### *Case No. (1):*

Female patient, 45 years with left radical mastectomy came for breast reconstruction. She received the whole course of radiotherapy and chemotherapy 2 years ago. The skin of the chest wall showed signs of radionecrosis (Fig. 1,a). The free TRAM was selected for the reconstruction.

The left axilla was exposed through the previous mastectomy scar to expose the thoracodorsal bundle. The thoracodorsal artery was identified entering the latissimus dorsi muscle and it was divided and clamped. The vein was identified at a more proximal level but its wall was thin and friable. The short stump of the vein and its pathological state would not allow its use for microvenous anastomosis. A search for another vein was done.

The pedicle supplying the serratus muscle (one artery and two venae comitantes) was dissected and divided distally for its potential use in microvascular anastomosis. The left cephalic vein was identified in the deltopectoral groove and dissected in the upper arm to gain a sufficient segment from it. The vein then was

clamped and divided distally and transposed into the axilla for venous anastomosis (Fig. 1,b).

A TRAM measured 32 x 14cm was raised based on the right deep inferior epigastric vessels. Arterial anastomosis was done between the deep inferior epigastric artery and the thoraco-dorsal artery. Venous anastomosis was done between the largest one of the venae comitantes of the deep inferior epigastric artery and the transposed cephalic vein. Another second venous anastomosis was done between the smaller venae comitans and the venae comitans of the artery supplying the serratus anterior muscle. The flap survived completely (Fig. 1,c).

*Case No. (2):*

Male patient, 52 years old suffered trauma to his left hand with a revolving machine. This resulted in total amputation of both left index and middle fingers at the level of the proximal phalanges with soft tissue laceration and skin loss over the stump of the amputated digits. The ischemia time was about 2 1/2 hours but the amputated parts were badly preserved as they were directly immersed in ice and cold water.

The amputated fingers and the stumps were examined under the operating microscope. The index finger showed severe injury of the vessels and extensive intimal damage. Its stump showed severe laceration of the vessels with large hematoma involving the dorsal and palmar aspects of the stump. There was also loss of the skin over the remaining stump. For these reasons it was not suitable for microvascular re-plantation.

The middle finger was in a better condition, but the two digital arteries were avulsed proximally. This finger was replanted. The arterial anastomosis was done between the digital artery on the ulnar side with the stump of the common digital artery at its beginning from the palmar arch using a 5cm vein graft from the dorsum of the foot.

Venous anastomosis was done between the dorsal vein of the amputated finger and a corresponding vein in the stump tissue a 3cm vein graft from the dorsum of the foot. To do a second venous anastomosis, there was no vein in the stump. One of the dorsal veins of the adjacent ring finger was exposed through longitudinal incision, dissected and divided close to the

PIP joint of the finger. The dissected segment of the vein was transposed to the middle finger and anastomosed directly to the dorsal vein of the amputated part. The replanted middle finger survived completely.

*Case No. (3):*

A psychotic male patient, 40 years old presented to us with self inflicted injury resulting in total amputation of the penis. The patient came to the hospital with good preservation of the amputated part (cold ischemia time was about 6 hours). The amputated part was cleanly cut but there was some laceration of the skin of the stump (Fig. 2,a).

The vessels and the nerves of the amputated part as well as the stump were identified and dissected. Trans-urethral Foley's catheter was used around which the urethra was sutured. The ventral aspects of the corpora were sutured. The penis was fixed by suturing the ventral skin of the penile shaft.

Arterial anastomosis was done between the divided ends of the two central arteries of the penis which was followed by closure of the dorsal aspect of the corpora. A third arterial anastomosis was done between the divided ends of the dorsal artery of the penis.

Venous anastomosis was done between the divided ends of one of the dorsal veins of the penis. A second venous anastomosis was intended to be done between another dorsal vein of the penis and its stump. For shortening of this stump due to the laceration of the skin, the right superficial inferior epigastric vein was identified, dissected, divided distally and transposed to the root of the penis to be anastomosed with the vein of the amputated part (Fig. 2,b).

The 2 dorsal nerves of the penis were sutured, the wound was closed and suprapubic cystostomy was done. The replanted penis survived completely (Fig. 3,c). Only a small part of skin at the root of the penis became sloughed and a skin graft was done for it 3 weeks later on.

*Case No. (4):*

A forty five years old carpenter presented with post traumatic adherent scar and tissue defect on the radial side of the left index finger. There was sensory loss on the whole radial side of the index and old neglected dislocation of the

proximal inter-phalangeal joint (PIP) due to a heavy knife injury 8 months ago (Fig. 3,a).

The adherent scar was excised and the dislocated joint was reduced and arthroplasty was done using perichondrial graft from the ear. A 9 cm nerve graft was harvested from the right anti-brachial nerve at the distal part of the right arm. The graft was used to bridge a defect of the radial digital nerve of the left index.

An arterialized venous flap measuring 5 x 2.5cm was raised from the volar aspect of the right forearm. The flap had 3 draining veins and one feeding afferent vein (Fig. 3,b). Two of the draining veins were anastomosed with two digital veins from the index by end to end anastomosis. For anastomosing the third vein, a proximal digital vein from the neighbouring middle finger was mobilized, transposed and used for anastomosis so as not to jeopardize the venous drainage of the index finger (Fig. 3,c). End to end arterial anastomosis between the radial digital artery of the index finger and the flap afferent vein was done, the flap donor site was closed by STSG from the thigh.

One day later the flap started to get swollen, edematous and its color became dark pink with glistening skin. The condition remained stationary until the 10<sup>th</sup> post-operative day where edema started to subside and healing of edges started to occur. By time the flap gained normal texture and stability. There was noticeable improvement in the flexion of the PIP (Fig. 3,d). Late sensory examination (10 months post-operative) revealed a 5mm two point discrimination at the radial side of the index finger over the flap.

#### *Case No. (5):*

Male patient, 26 years old presented to us with total loss of his penis. The patient had this problem after application of tight crepe bandage on the penis for control of urethral bleeding which ended with sloughing of the whole penis. Several surgical procedures were done to lengthen the remaining stump but without gaining much benefit (Fig. 4,a).

Total phalloplasty was done using the radial forearm flap. The flap length measured 14cm and its width measured 15cm in its proximal end and 13cm in its distal end. Two strips of skin, each of them measured 1cm were deepithelialized around 3cm strip of skin to recon-

struct the neourethra. The flap included the radial artery and its 2 venae comitantes, cephalic vein, medial and lateral cutaneous nerves of the forearm.

Through a midline incision and transverse incision through the previous scar, the deep inferior epigastric vessels on the left side were exposed, dissected for a sufficient length, divided and reflected down. The remaining part of the penile root was explored, the end of the urethra, the penile stump and the two dorsal penile nerves were identified and exposed.

Arterial anastomosis was done between the radial artery of the flap and the deep inferior epigastric artery (end to end). After clamp release, there was profuse bleeding from the anastomotic site. This bleeding was not controlled by more sutures and the ends of the vessels became lacerated. So, the arterial anastomosis was revised immediately and the flap became well perfused.

The venae comitant accompanying the deep inferior epigastric artery was too friable and small. It was shortened till adequate size was reached. This needed a vein graft to complete the venous anastomosis. A small vein graft from the cephalic vein of the flap was used for venous anastomosis between the venae comitant of the radial artery and the venae comitant of the deep inferior epigastric artery. This anastomosis was not patent. For this reason the deep inferior epigastric vessels on the contralateral side were exposed. The venae comitant though appearing better than the other side; still, it has not the criteria of completely healthy vein. A long vein graft was harvested from the left great saphenous vein and used for venous anastomosis between the flap vein and the contralateral venae comitant of the deep inferior epigastric artery.

Neural repair was done between the 2 dorsal penile nerves and the medial and lateral cutaneous nerves of the flap. Flap was fashioned in its place and supra-pubic cystostomy was done (Fig. 4,b).

Thirty six hours after the operation, the flap became congested (Fig. 4,c). Some stitches were removed, multiple small incisions with local injection of heparin started. Few hours later, the congestion was severe and the decision was to be explored. On exploration, the vein graft

was thrombosed till the ends of the anastomosed veins. The graft was resected and the vein of the flap was shortened, irrigated till satisfactory bleeding was obtained. The great saphenous vein of the right thigh was exposed, divided just above the knee and dissected till the saphenofemoral junction (Fig. 4,d). The vein was transposed and venous anastomosis was done between it and the vein of the flap. This could salvage the failing transplant and the new penis survived completely (Fig. 4,e).

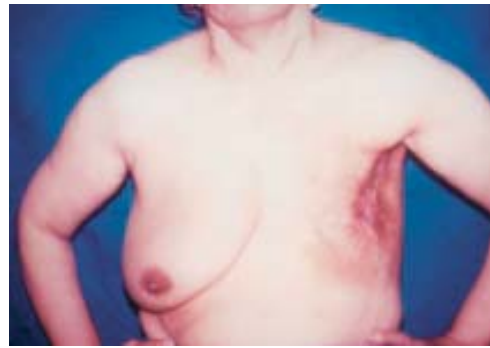

Fig. (1): a: Patient No. (1) with left radical mastectomy.

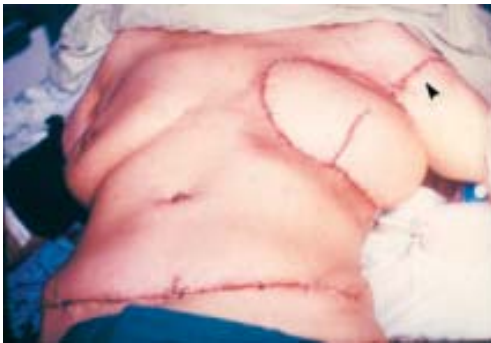

Fig. (1): b: Immediate post operative view showing the reconstructed breast and the incision in the left arm through which the cephalic vein is dissected and transposed.

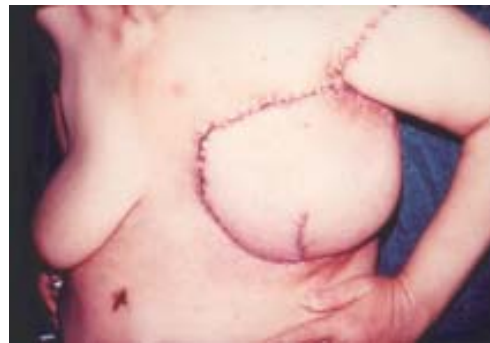

Fig. (1): c: Complete flap survival.

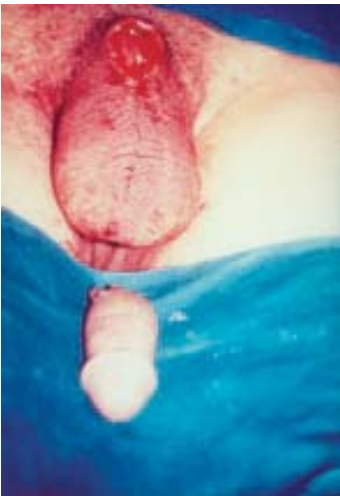

Fig. (2): a: Patient No. (3) with complete amputation of the penis.

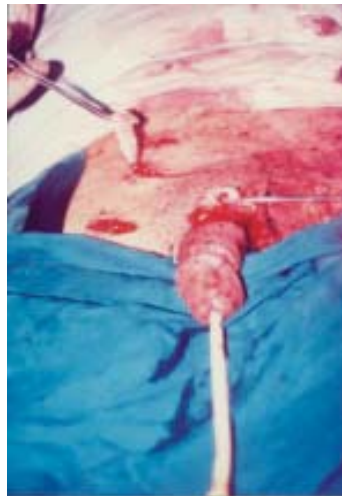

Fig. (2): b: Intraoperative view showing the replanted penis and the incision through which the right superficial inferior epigastric vein is exposed and dissected.

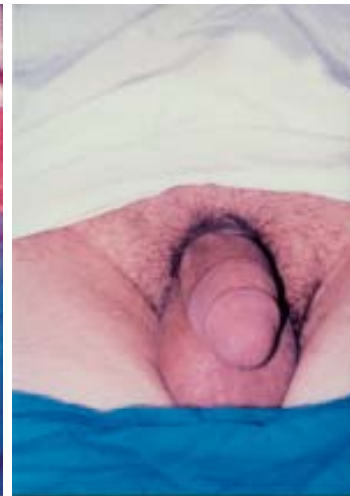

Fig. (2): c: Complete survival of the replanted penis.

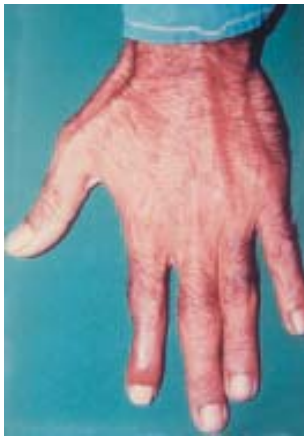

Fig. (3): a: Patient No. (4) with adherent scar on the radial side of the left index finger with stiff proximal interphalangeal joint.

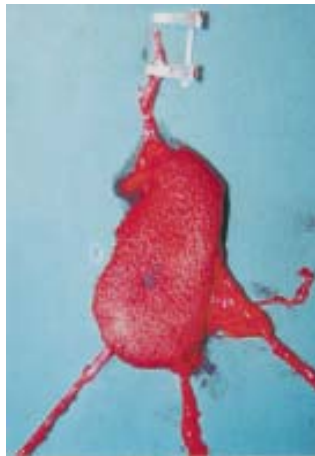


Fig. (3): b: The arterialized venous flap with 3 draining veins and one feeding afferent vein.

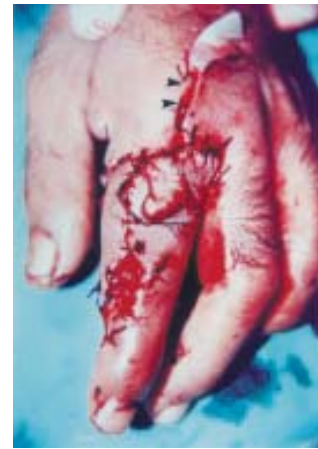

Fig. (3): c: Immediate post-operative view showing the flap in place and the incision in the dorsum of the adjacent finger through which the dorsal digital vein is dissected and transposed.

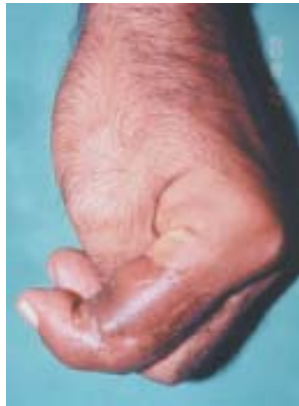

Fig. (3): d: Late post-operative view showing complete flap survival and flexion of the proximal interphalangeal joint.

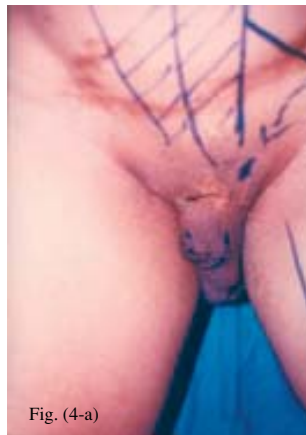

Fig. (4)-a

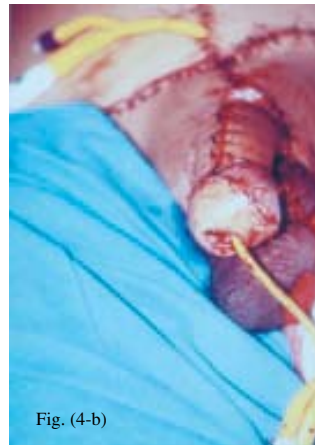

Fig. (4)-b

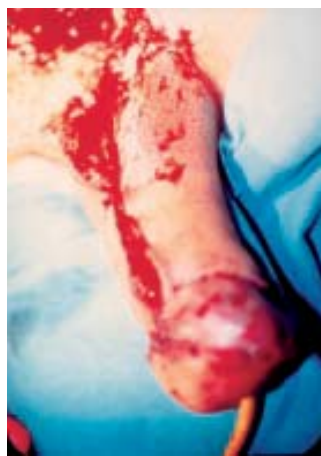

Fig. (4)-c

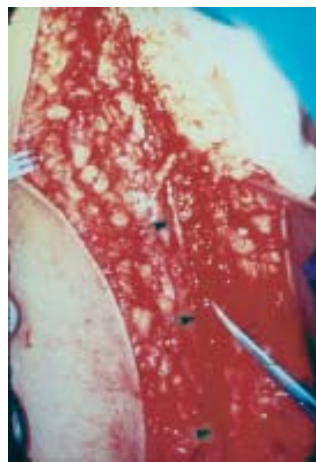

Fig. (4)-d

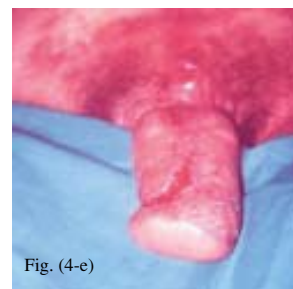

Fig. (4)-e

Fig. (4):  
 a: Patient No. (5) with total penile loss.  
 b: Intraoperative view showing the reconstructed phallus by the radial forearm flap.  
 c: Thirty six hours post-operatively with severe congestion of the reconstructed penis.  
 d: Exposure and dissection of the saphenous vein of the right thigh.  
 e: Complete survival of the reconstructed penis.

## DISCUSSION

Free composite tissue transfers offer a reliable, single-stage reconstruction with low morbidity. Adequate recipient arteries and veins are essential in obtaining a successful flap transfer. Under certain circumstances there is no available suitable recipient vein for the venous anastomosis. This is commonly met in reconstructive surgery of the head and neck following cancer ablation and postoperative irradiation.

The problem of venous drainage in free flaps to the head and neck was addressed by Meagher et al. [5]. They advocated the use of local veins even if they were of small caliber. This was objected by Kim and Chandrasekhar [1]. They found that a free flap venous anastomosis to a small caliber local vein risks thrombosis. This is especially true when the ultimate drainage pattern of these veins is unclear, because of prior surgery and/or radiation.

If there is no adequate local veins due to irradiated scarred neck from previous surgery, radical neck dissection, cervical soft tissue infection, radiation therapy or a combination of these [1], the use of vein grafts may be necessary though it has been implicated in higher flap failure rates [6,7]. Again the use of interposition vein grafts to the undamaged contralateral vein was not preferred as it requires two anastomoses and is associated with an increased risk of thrombosis [1]. Another alternative is transposition of a long segment from near-by large vein to obviate the need for these vein grafts.

Cephalic vein transposition in microvascular reconstruction of major head and neck defects was reported and described by several authors [1-4]. It has many advantages over the use of interpositional vein grafts [1].

- 1- It requires only one venous anastomosis.
- 2- A long pedicle can be harvested to reach the mid-face or contralateral neck without undue tension.
- 3- The cephalic-subclavian system is high-flow, low-pressure system.
- 4- This vein is located outside ablative surgical field, or radiated tissue, therefore it is undamaged.
- 5- The vein caliber is well suited for microvascular anastomosis.

The same principle can be also applied in microvascular reconstruction of the breast after

mastectomy. All these patients were previously subjected to irradiation with its debatable effect on the state of the recipient vessels.

Reports on the patency of microvascular anastomoses in irradiated tissues are controversial and not conclusive. In the early days of microsurgery, it was generally recommended that the use of irradiated vessels in microvascular procedures should be avoided [8-10]. Later on, it has been shown that in irradiated tissues, the patency of microvenous anastomosis is reduced significantly whereas the patency of microarterial anastomosis is not altered [11]. However, Mulholland et al. [2] has comparable free flap survival rates in the irradiated and non irradiated patients. They reserved the use of vein grafts and cephalic loops in situations where the recipient vessels are not available. They do not find that the long-term radiation effect is significant enough to necessitate longer angioaccess procedures in the presence of adequate local radiated recipient vessels. In another recent study [12], the success of microvascular anastomosis and the overall flap survival was not affected by preoperative irradiation.

However, in some cases the local veins are friable and easily injured during dissection that would necessitate performing the venous anastomosis with a healthy vein away from the area of scarring and irradiation. This was the situation in case No. (1) where the cephalic vein was transposed from the arm to the axilla to be used as venous drainage for the free TRAM. In this situation, intraoperative finding of pathological vein in the irradiated area is the indication for vein transposition.

In replantation surgery, the anastomosis of multiple veins has shown to improve the outcome [13,14]. There is general recommendation to repair one or two arteries and two or three veins for the amputated part and for each artery at least two veins have to be done. In some cases which is associated with some lacerations of the stump no near by available veins could be detected. Instead of interposing the gap by vein grafts with their technical difficulties and risks, transposition of one of the digital veins from the adjacent finger can be done. This was the situation in case No. (2). Also, the same principle was applied in the case of penile replantation case No. (3), where the superficial inferior epigastric vein was mobilized and transposed to

the stump to provide another drainage for the replanted penis.

There is evidence in the literature to suggest that when two venous anastomoses are performed, there is less likelihood of flap failure [15]. Two venous anastomoses are our standard in free flap surgery, if there is no available vein in the area we would not hesitate to transpose a large nearby vein to add another vein for the second venous anastomosis. The external jugular vein is commonly used in head and neck reconstruction after being divided cephalically.

Arterialized venous flaps were added to the armamentarium of Plastic Surgeons since 1987 [16]. Since that time several reports on their uses for digital reconstruction were published [17-19]. All experimental and clinical studies [20-24] showed that at least two veins should drain the A.V. flap and the success rate is greatly increased when 3 veins are used for their drainage. So, whenever possible this flap should be drained by three veins. However, the use of three digital veins from the same digit has to be avoided so as not to jeopardize the venous drainage of the digit itself. Thus only two veins from the affected digit were used and the third one has to be transposed from the adjacent digit. This was what we did in case No. (4). In the long term follow up of this case the patient did not develop any edema in the operated digit.

Venous thrombosis is more common than arterial thrombosis after free flap surgery [25-26]. In the series of Kroll et al. [27] the incidence of venous thrombosis was 54% while that of arterial thrombosis was 20%. 59% of these venous thrombi occurred before the end of the first postoperative day and they can be easily diagnosed than arterial thrombosis. So, the chance for exploration is great. On exploration, sometimes a segment from the recipient vein has to be resected which may make it short to be used again for reanastomosis. In such situations venous transposition and anastomosing this vein to the flap will provide rapid and sure venous drainage to a large draining vein. This is what was done in case No. (5) where the saphenous vein was transposed from the thigh and used to drain the failing transfer.

*To summarize, there are some situations in which vein transposition is indicated:*

1- Local veins are available but their status (due to irradiation) or length (due to shortening

or injury during dissection) would not permit their uses in microvenous anastomosis. This is commonly seen in head and neck and breast reconstruction after irradiation. The vein to be used is the cephalic vein.

2- Local veins are available but their numbers are not sufficient for microvenous anastomosis if more than one venous anastomosis is planned to be done. This is commonly seen in replantation surgery. The vein to be used is the dorsal digital vein from the adjacent digit during replantation of amputated digits. Another example is transposition of the superficial inferior epigastric vein to the root of the penis in penile replantation.

3- Local veins are available but they could not be used for fear of jeopardizing the venous drainage of the area. The example is the use of arterialized venous flap with 3 venous anastomoses for digital coverage. Two veins will be used from the affected digit and the third one will be borrowed from the adjacent digit to avoid compromising the venous drainage of this digit and the post operative edema.

4- Local veins are available and they are already used in the anastomosis, but venous thrombosis occurred that necessitated revision of this anastomosis. When the remaining stump length is not sufficient due to shortening, vein transposition is indicated to salvage the failing replant or transfer.

In conclusion vein transposition can be another alternative for interpositional vein grafts. It can give a long pedicle that is located outside the ablative surgical field or radiated tissues. It requires only one venous anastomosis that drains to a high-flow low-pressure system.

## REFERENCES

- 1- Kim K.A. and Chandrasekhar B.S.: Cephalic vein in salvage microsurgical reconstruction in the head and neck. *Brit. J. Plast. Surg.*, 51: 2-7, 1998.
- 2- Mulholland S., Boyd J.B., McCabe S., et al.: Recipient vessels in head and neck microsurgery: Radiation effect and vessel access. *Plast. Reconstr. Surg.*, 92: 628-632, 1993.
- 3- Horng S.Y. and Chen M.T.: Reversed cephalic vein: A lifeboat in head and neck free flap reconstruction. *Plast. Reconstr. Surg.*, 92: 752-753, 1993.
- 4- Hallock G.G.: Venous outflow simplified by the cephalic vein loop. *Ann. Plast. Surg.*, 21: 427-429, 1988.

- 5- Meagher A.P., Sheridan B.F., Jensen M.J., et al.: Venous drainage of free flaps following radical neck dissection. *Aust. NZJ Surg.*, 61: 903-908, 1991.
- 6- Tsai T.M., Bennett D.L., Pederson W.C., et al.: Complications and vascular salvage of free-tissue transfers to the extremities. *Plast. Reconstr. Surg.*, 82: 1022, 1988.
- 7- Freedman A.M. and Meland N.B.: Arteriovenous shunts in free vascularized tissue transfer for extremity reconstruction. *Ann. Plast. Surg.*, 23: 123, 1989.
- 8- Ostrup L.T. and Fredrickson J.M.: Reconstruction of mandibular defects after radiation using a free living bone graft transferred by microvascular anastomoses: An experimental study. *Plast. Reconstr. Surg.*, 55: 563, 1975.
- 9- O'Brien B.: *Microvascular reconstructive surgery*, Edinburgh: Churchill-Livingstone, 1977.
- 10- Acland R.D. and Flynn M.B.: Immediate reconstruction of oral cavity and oropharyngeal defects using microvascular free flaps. *Am. J. Surg.*, 136: 419, 1978.
- 11- Watson J.S.: Experimental microvascular anastomoses in radiated vessels: A study of the patency rate and the histopathology of healing. *Plast. Reconstr. Surg.*, 63: 525, 1979.
- 12- Singh B., Cordeiro P.G., Santamaria E., et al.: Factors associated with complications in microvascular reconstruction of head and neck defects. *Plast. Reconstr. Surg.*, 103: 403, 1999.
- 13- Kleinert H.E., Jablon M. and Tsai T.M.: An overview of replantation and results of 347 replants in 245 patients. *J. Trauma.*, 20: 290, 1980.
- 14- Tamai S.: Twenty years experience of limb replantation: Review of 293 upper extremity replants. *J. Hand Surg.*, 7: 549, 1982.
- 15- Harashina T.: Analysis of 200 free flaps. *Br. J. Plast. Surg.*, 41: 33, 1988.
- 16- Yoshimura M., Shimada T., Imura, et al.: The venous skin graft method for repairing skin defects of the fingers. *Plast. Reconstr. Surg.*, 79: 243, 1987.
- 17- Inou G. and Suzuki K.: Arterialized venous flap for treating multiple skin defects of the hand. *Plast. Reconstr. Surg.*, 91: 299, 1993.
- 18- Inu G. and Tamura Y.: One-stage repair of both skin and tendon digital defects using arterialized venous flap with palmaris longus tendon. *J. Reconstr. Microsurg.*, 7: 339, 1996.
- 19- Takeuchi M., Sakurai H., Sasaki K., et al.: Treatment of finger avulsion injuries with innervated arterialized venous flaps. *Plast. Reconstr. Surg.*, 106: 881, 2000.
- 20- Inada Y., Fukui A., Tamai S., et al.: The arterialized venous flap: Experimental studies and a clinical case. *Br. J. Plast. Surg.*, 46: 61, 1993.
- 21- Klein C. Kovacs A. and Stuckenson T.: Free arterialized venous forearm flaps for intra-oral reconstruction. *Br. J. Plast. Surg.*, 50: 166, 1997.
- 22- Reynosa R., Espinosa A., Mendoza M., et al.: The arterialized anti-brachial skin flap for hand reconstruction. *J. Reconstr. Microsurg.*, 13: 267, 1997.
- 23- Woo S.h., Kim S.E., Lee T.H., et al.: Effect of blood flow and venous network on survival of arterialized venous flaps. *Plast. Reconstr. Surg.*, 101: 1280, 1998.
- 24- Zakaria K.S., Hemeda M.M. and Sherif M.E.: Arterialized venous flaps: Experimental and clinical study. M.d. Thesis Plastic Surgery. Ain Shams University, Cairo, Egypt, 2001.
- 25- Lineaweaver W.C. and Buncke H.J.: Complications of free flap transfers. *Hand Clin.*, 2: 347, 1986.
- 26- Hidalgo D.A. and Jones C.E.: The role of emergent exploration in free tissue transfer: A review of 150 consecutive cases. *Plast. Reconstr. Surg.*, 86: 492, 1990.
- 27- Kroll S.S., Schusterman M.A., Reece G.P., et al.: Timing of pedicle thrombosis and flap loss after free-tissue transfer. *Plast. Reconstr. Surg.*, 98: 1230, 1996.